Malaysian Journal of Medical Sciences, Vol. 16, No. 4, Pg 34-41, October - December 2009

ORIGINAL ARTICLE

Superselective Embolisation in Acute Lower Gastrointestinal Haemorrhage: A Single Institution Experience

Ahmad Razali Md Ralib[1], Rozman Zakaria[2], Zahiah Mohamad[2], Ahmad Sobri Muda[2]

[1] *Department of Radiology, Kulliyyah (Faculty) of Medicine, International Islamic University Malaysia, P.O. Box 141, 25710 Kuantan, Pahang, Malaysia*
[2] *Department of Radiology, Faculty of Medicine, Universiti Kebangsaan Malaysia, Jalan Yaakob Latif, Bandar Tun Razak, 56000 Kuala Lumpur, Malaysia*

Submitted: 10 Jul 2009
Accepted: 16 Sep 2009

Abstract

Background: **Superselective embolisation has been recognised as integral in the management of lower gastrointestinal haemorrhage. It has also reduced the need for emergency surgery. The objective of this case series was to describe the lower gastrointestinal haemorrhage cases seen in our centre, its diagnosis and the role of superselective embolisation in patient management.**

Methods: **All patients who underwent superselective embolisation from January 2008 until April 2009 in our centre were analysed. Data were collected from the hospital electronic medical records.**

Results: **Four patients (three males) with a mean age of 81 years were analysed. Multidetector computerised tomography and digital subtraction angiography were positive in all patients. Superselective embolisation with platinum microcoils was performed in all patients (n = 4). Technical success was achieved in all patients (100%).**

Conclusion: **Superselective embolisation in the treatment of lower gastrointestinal haemorrhage is safe and effective with a very high technical success rate.**

Keywords: *gastrointestinal haemorrhage, therapeutic embolisation, spiral computerised tomography, medical sciences*

Introduction

Massive lower gastrointestinal haemorrhage (LGIH), which is defined as bleeding in the bowel beyond the ligament of Treitz, remains a challenge in its diagnosis and management. It is usually associated with a mortality rate of 5 to 12% and can approach 40% in severe haemorrhage (1).

Diagnosing the cause and site of the active haemorrhage remains a problem. Multiple modalities are available, such as colonoscopy, radionuclide imaging, multidetector computerised tomography (MDCT) mesenteric angiography and digital subtraction angiography (DSA), all of which have their own advantages and disadvantages (2). However, with the recent advancement in CT technology, MDCT mesenteric angiography has become the modality of choice in the detection and localisation of the sites of haemorrhage (3–5). Emergency surgical interventions in massive LGIH usually are associated with high mortality rates and high re-bleeding rates(1). Bookstein et al. first described intra-arterial embolisation using modified autogenous blood clots for LGIH (6). However, this method suffered criticisms because of its association with ischaemic complications (7).

Recent advancement in technology and the availability of smaller coaxial microcatheters up to 2 F in size and guidewires have made superselective angiography and embolisation of the causative distal bleeding artery technically feasible. This has enabled superselective embolisation (SSE) to be performed safely and with significant reduction in the risk of postembolisation ischaemia. The technical success of SSE is usually around 97 to 100% (8–10). The majority of these patients do not need further interventions after the embolisation (8–10). Long-term follow-up in patients who underwent SSE also yielded favourable results, with less than 20% requiring readmission for further LGIH (11, 12). The objectives of this case series were to describe the LGIH cases seen in our centre, its diagnosis and the role of SSE in patient management.

www.mjms.usm.my © Penerbit Universiti Sains Malaysia, 2009
For permission, please email:mjms.usm@gmail.com

Materials and Methods

All patients who underwent SSE for LGIH from January 2008 to April 2009 in Universiti Kebangsaan Malaysia Medical Centre were identified retrospectively via the hospital electronic medical record (EMR). Review of the patients' EMR, which included demography, site of haemorrhage and preembolisation examinations, was also performed. All patients with suspected LGIH in our centre were referred to the on-call interventional radiologist (IR) or IR fellow. Since January 2008, all patients with suspected LGIH underwent MDCT mesenteric angiography as a preembolisation examination. The MDCT images were interpreted by the on-call IR, either in the hospital or through the internet from home. Only patients with positive MDCT (with contrast extravasation into the bowel lumen) underwent DSA of the mesenteric arteries with an intention for SSE (Figure 1, 2 and 3). With this information, the angiography team was mobilised. In patients with negative MDCT (no contrast extravasation into the bowel lumen), no DSA was performed. However, if the patient re-bled, a repeat MDCT was urgently performed.

Nuclear scintigraphy, using technetium 99m (99mTc) red blood cell-labelling, is available in our centre. However, this examination was noted to be time consuming and with poor anatomic localisation (13). Yoon et al. (3) had observed that MDCT gives a sensitivity, specificity, accuracy, positive predictive value and negative predictive value of 90.9%, 99%, 97.6%, 95% and 98%, respectively, for detecting acute gastrointestinal haemorrhage. They also showed that the location of contrast extravasation shown on MDCT corresponded exactly with the contrast extravasation on DSA. With this information, nuclear scintigraphy using 99mTc red blood cell-labelling was only reserved for chronic LGIH where other investigations had failed. MDCT was the first choice in acute LGIH.

MDCT was performed with a 64-slice MDCT (Siemens Sensation 64) in multiple phases. DSA was performed with a DSA machine (Single plane Toshiba KXO 200 & Biplane Philips Allura X-Per FD20/10). Coeliac, gastroduodenal, superior mesenteric and inferior mesenteric arteriograms were performed in all patients. A positive DSA was defined when there was active contrast extravasation seen (Figure 1, 2 and 3). In patients with a positive DSA, a coaxial microcatheter with a micro guidewire (FasTracker-325 microcatheter; Boston Scientific) was introduced just proximal to the bleeding site. A superselective arteriogram (SSA) was then performed to further demonstrate the active contrast extravasation (Figure. 1, 2 and 3). Embolisation was then performed with platinum microcoils (Hilal Embolisation Microcoils; Cook) of variable length after consultation with the surgical team. A repeat SSA was performed postembolisation. A technical success was defined when hemostasis was secured with no active contrast extravasation seen in the postembolisation arteriography (Figure 1, 2 and 3).

Results

From January 2008 until April 2009, there were 4 patients who presented with LGIH and had SSE performed. The mean age of the patients was 81 (73 to 88) years. There were three males and one female. MDCT of the mesenteric arteries was positive in all patients in which contrast extravasation was seen into the bowel lumen. On MDCT, the location of haemorrhage was seen in the ascending colon (n = 2), descending colon (n = 1) and splenic flexure (n = 1). On DSA, contrast extravasation was seen from the superior mesenteric (n = 2) and inferior mesenteric (n = 2) arteries. All embolisation procedures were performed with platinum microcoils (n = 4). There was complete cessation of haemorrhage in all 4 patients postembolisation, with a technical success rate of 100% (Table 1). The time interval between the MDCT and DSA was less than 3 hours, except for in one patient. One patient had a longer time interval of 7 hours between the MDCT and DSA due to some logistical problems.

Discussion

Superselective embolisation in the management of acute LGIH has been increasingly accepted in most centres all over the world. This method was noted to be safe and effective in the acute management of LGIH. SSE also played a major role in patients with poor comorbid conditions. It allows for rapid haemostasis of the bleeding arteries, enabling the patient to be resuscitated and stabilised prior to a major surgery. The first known attempt of transcatheter embolisation was described by Bookstein et al. in 1974 using modified autogenous blood clots (6). However, early reports observed a high percentage of bowel necrosis postembolisation (7). This was due to the use of larger catheters (6F Cobra Catheter), which did not allow for a SSE to be performed.

However, with the current technology, especially with the availability of microcatheters, platinum microcoils and polyvinyl alcohol (PVA)

Figure 1A

Figure 1B

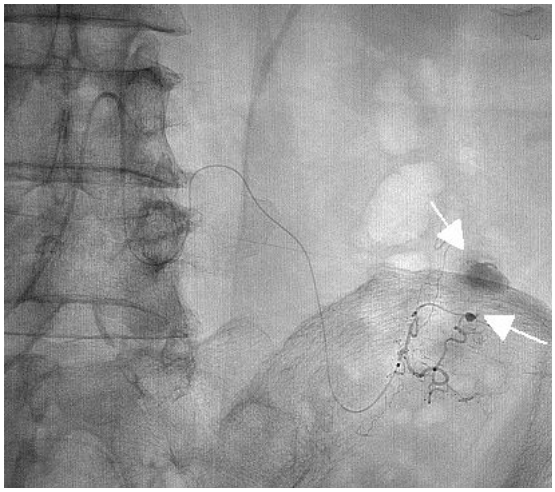

Figure 1C

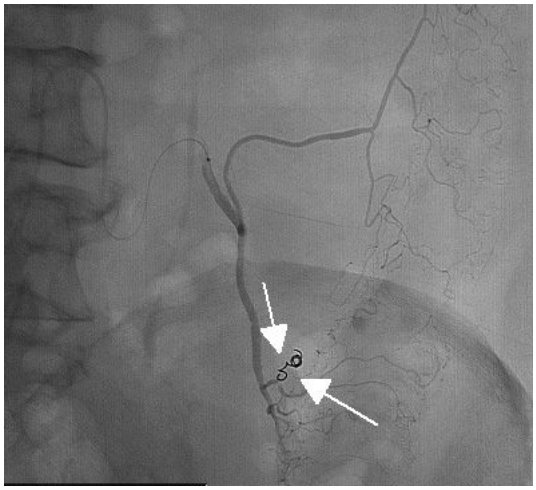

Figure 1D

An 88-year-old man with massive LGIH. Initial colonoscopy failed to determine the cause due to the presence of blood clots.

Figure 1A : Axial MDCT showing contrast extravasation in the descending colon (arrows)
Figure 1B : Inferior mesenteric arteriogram showing contrast extravasation from the descending branch of the left colic artery (arrow)
Figure 1C : Superselective arteriogram (SSA) of the descending branch of the left colic artery showing contrast extravasation at the same location (arrows)
Figure 1D : SSE was performed with 2 platinum microcoils (arrows) with no residual contrast extravasation seen postembolisation

particles, a SSE of the bleeding arteries can be performed at the level of the vasa recta or marginal artery of Drummond. Luchtefeld et al. reported a 82% technical success rate with only 6% of patients developing bowel necrosis (14). Funaki et al. also reported a 96% success rate with 7% of patients developing bowel necrosis (15). In the recent literature, the results have been better. Tan et al. reported a 97% technical success rate with only 3% of patients developing postembolisation ischaemia (9). Lipof et al. reported a 97% technical success rate with 7% of patients developing postembolisation ischaemia (8). Koh et al. reported a 100% technical success rate with 5% of patients developing postembolisation ischaemia (10). This is similar to our case series, in which we had achieved a 100% technical success rate.

On long-term follow-up, Ahmed et al. reported that only 4 out of 20 patients were readmitted to the hospital for further acute LGIH at 1, 2, 12 and 16 months (11). Maleux et al. reported that 8 out of 39 patients developed re-bleeding post-SSE, with 6 of them re-bleeding within the first 30 days (12). On long-term follow-up, the estimated survival

Figure 2A

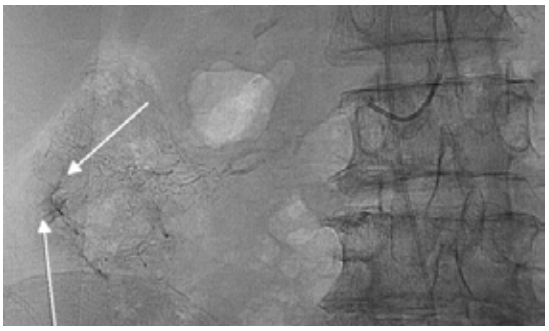

Figure 2B

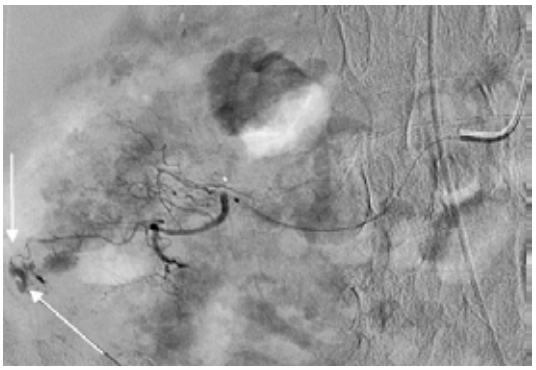

Figure 2C

Figure 2D

An 81-year-old man with end-stage renal failure presented with massive LGIH.

Figure 2A : Axial MDCT showing contrast extravasation in the ascending colon (arrows)
Figure 2B : Superior mesenteric arteriogram showing contrast extravasation from the distal branches of the middle colic artery (arrows)
Figure 2C : SSA showing more obvious contrast extravasation from the distal branches of the middle colic artery (arrows)
Figure 2D : SSE was performed with 2 platinum microcoils (arrows) with no residual contrast extravasation seen postembolisation

rates of their patients were 70.6%, 56.5%, and 50.8% after 1, 3, and 5 years, respectively.

There are many types of embolic materials that can be used in SSE, such as platinum microcoils, PVA particles, glue and gelfoam (8–12). In the initial days, intraarterial vasopressin infusion was the method of choice in LGIH, which leads to arterial vasoconstriction and bowel contraction. This then leads to a lower blood flow into the affected bowel. However, these patients require intensive care unit (ICU) monitoring due to complications, such as myocardial ischaemia, peripheral ischaemia, hypertension, arrhythmias and hyponatremia (1). Today, intraarterial vasopressin infusion is no longer used, and the other embolic materials mentioned above are used (8–12). In our series, platinum microcoils were used in all patients.

From these case series and literature reviews, we would like to suggest an algorithm for the management of LGIH, as shown in Figure 4. This algorithm is applicable only in centres with MDCT and IR services. However, in centres without an IR service, MDCT of the mesenteric arteries in multiple phases should be performed to localise the site of the acute LGIH. With the MDCT findings, the patient can be referred to the nearest centre with IR service if the patient is fit and stable. If the patient is not fit and is unstable, the MDCT findings will help the surgeon to localise the site of haemorrhage and perform a segmental colectomy.

Figure 3A

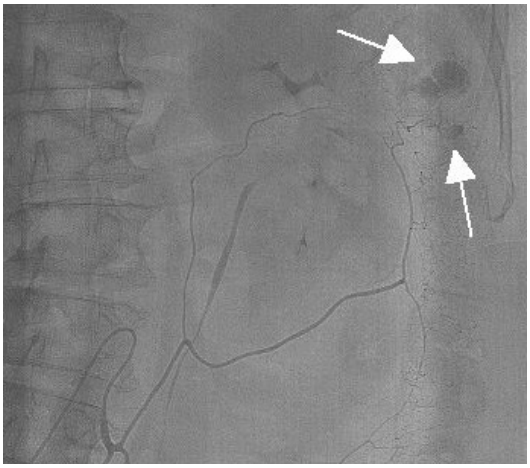

Figure 3B

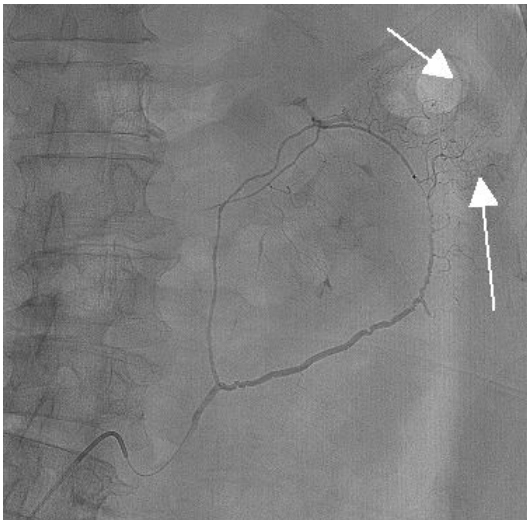

Figure 3C

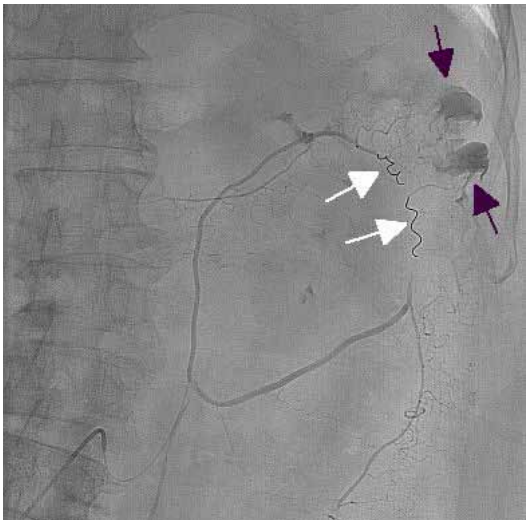

Figure 3D

A 73-year-old man with a 4-day history of fresh rectal bleeding. Colonoscopy showed diverticular disease with extensive blood clots.

Figure 3A : Axial MDCT showing contrast extravasation in the splenic flexure (arrows)
Figure 3B : Inferior mesenteric arteriogram showing suspicious contrast extravasation from the ascending branch of the left colic artery (arrows)
Figure 3C : SSA of the ascending branch of the left colic artery showing contrast extravasation (arrows)
Figure 3D : SSE was performed with 2 platinum microcoils (white arrows). Note the pooling of contrast in the region of the splenic flexure from the extravasation of the previous arteriograms (black arrows)

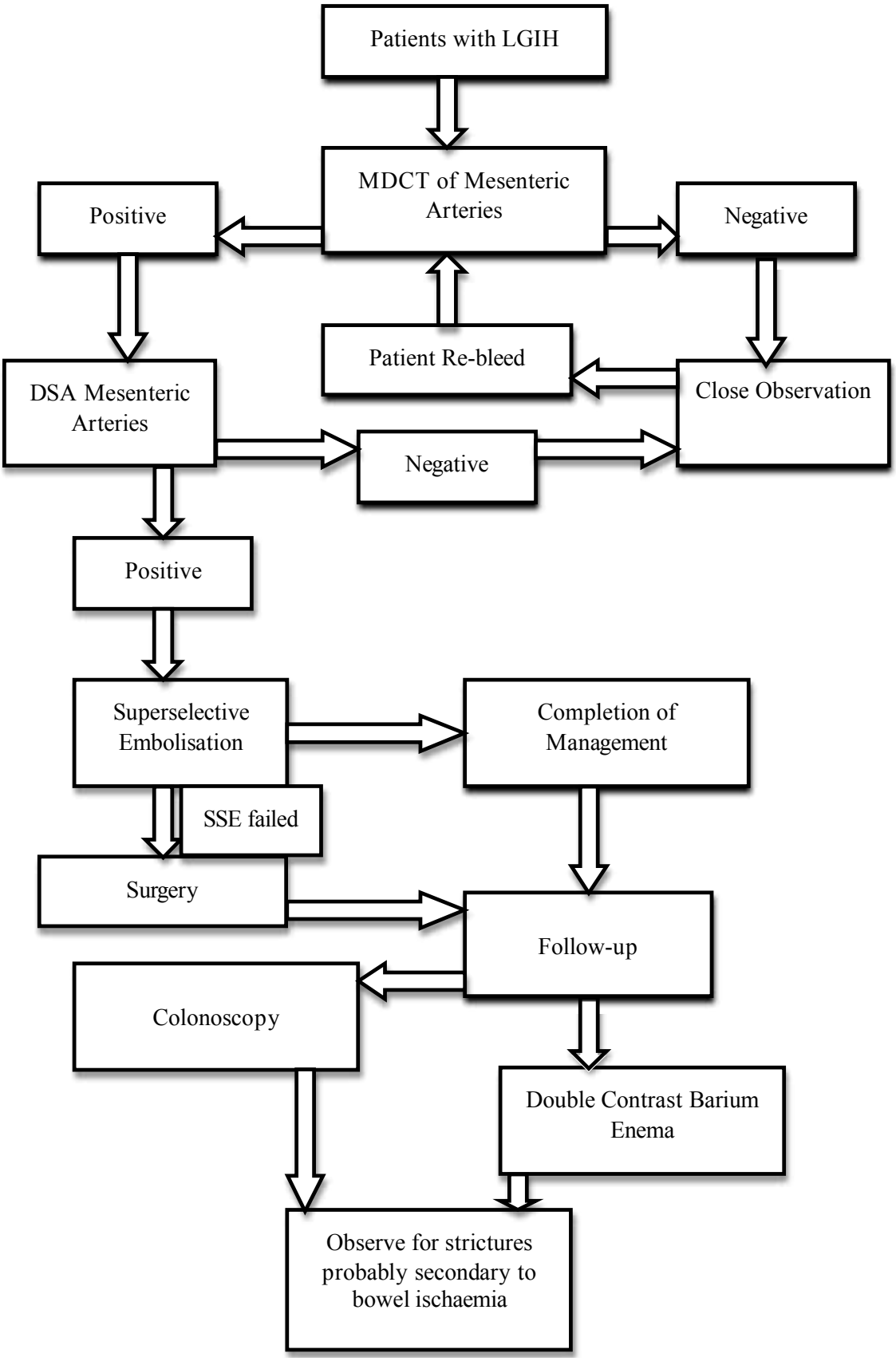

Figure 4: Algorithm in the management of LGIH

Table 1: Details of patients and site of haemorrhage

No.	Age / Sex	Location of contrast extravasation in:		Time Interval between CT and DSA	Bleeding artery	Treatment	Results
		MDCT	DSA				
1	88/M	Descending Colon	IMA	2 hours	Left Colic Artery	2 microcoils	Hemostasis secured
2	81/M	Caecum & Ascending Colon	SMA	7 hours	Middle Colic Artery	2 microcoils	Hemostasis secured
3	73/M	Splenic Flexure	IMA	2 hours	Left Colic Artery	2 microcoils	Hemostasis secured
4	83/F	Ascending Colon	SMA	3 hours	Right Colic Artery	2 microcoils	Hemostasis secured

Abbreviations: M=male, F=female, SMA=superior mesenteric artery, IMA=inferior mesenteric artery

Conclusion

SSE has a major role in the management of acute LGIH. In centres with IR services, it should be considered as the first choice of treatment. This is due to a very high technical success rate, reaching almost 100%, coupled with a very low incidence of postembolisation ischaemia.

Acknowledgements

The authors would like to thank all the radiologists, radiographers and staff nurses in the CT scan and angiography suite, Department of Radiology, Universiti Kebangsaan Malaysia Medical Centre for all their contributions in this study and patient management.

Author's contributions

Conception and design, final approval of article: ZM, ASM
Data collection: ARMR, RZ, ASM
Data analysis and interpretation: ARMR, RZ, ASM
Darfting of the article and critical revision: ARMR, ASM
Provision of study materials or patients: ARMR, RZ, ZM, ASM

Correspondence

Dr. Ahmad Razali bin Md Ralib
MBBS (UM) MMed (Radiology) USM
Department of Radiology
Kulliyyah (Faculty) of Medicine
International Islamic University Malaysia
P.o Box 141
25710 Kuantan
Pahang, Malaysia
Tel: +609-571 6400
Email: arazali@iiu.edu.my

References

1. Hoedema R, Luchtefeld M. The Management of Lower Gastrointestinal Haemorrhage. *Dis Colon Rectum*. 2005;**48**:2010–2024.

2. Laing CJ, Tobias T, Rosenblum DI, Banker WL, Tseng L, Tamarkin SW. Acute Gastrointestinal Bleeding: Emerging Role of Multidetector CT Angiography and Review of Current Imaging Techniques. *Radiographics*. 2007;**27**:1055–1070.

3. Yoon W, Jeong YY, Shin SS, Lim HS, Song SG, Jang NG, et al. Acute Massive Gastrointestinal Bleeding: Detection and Localization with Arterial Phase Multi-Detector Row Helical CT. *Radiology*. 2006;**239**:160–167.

4. Scheffel H, Pfammatter T, Wildi S, Bauerfeind P, Marincek B, Alkadhi H. Acute gastrointestinal bleeding: detection of source and etiology with multi-detector-row CT. *Eur Radiol*. 2007;**17**:1555–1565.

5. Jaeckle T, Stuber G, Hoffmann M, Jeltsch M, Schmitz B, Aschoff A. Detection and localization of acute upper and lower gastrointestinal (GI) bleeding with arterial phase multi-detector row helical CT. *Eur Radiol*. 2008; **18**:1406–1413.

6. Bookstein JJ, Chlosta EM, Foley D, Walter JF. Transcatheter hemostasis of gastrointestinal bleeding using modified autogenous clot. *Radiology*. 1974;**113**:277–285.

7. Rosenkrantz H, Bookstein JJ, Rosen RJ, Goff WB. Postembolic colonic infarction. *Radiology*. 1982;**142**:47–51.

8. Lipof T, Sardella WV, Bartus CM, Johnson KH, Vignati PV, Cohen JL. The efficacy and durability of super-selective embolisation in the treatment of lower gastrointestinal bleeding. *Dis Colon Rectum*. 2008;**51**:301–305.

9. Tan K, Wong D, Sim R. Superselective Embolisation for Lower Gastrointestinal Haemorrhage: An Institutional Review Over 7 Years. *World J Surg*. 2008;**32**:2707–2715.

10. Koh DC, Luchtefeld MA, Kim DG, Knox MF, Fedeson BC, Van Erp JS, et al. Efficacy of transarterial embolisation as definitive treatment in lower gastrointestinal bleeding. *Colorectal Dis*. 2009;**11**:53–59.

11. Ahmed TM, Cowley JB, Robinson G, Hartley JE, Nicholson AA, Lim M, et al. Long term follow up of transcatheter coil embolotherapy for major colonic haemorrhage. *Colorectal Dis*. 2009. Apr 13. [Epub ahead of print].

12. Maleux G, Roeflaer F, Heye S, Vandersmissen J, Vliegen AS, Demedts I, et al. Long-term outcome of transcatheter embolotherapy for acute lower gastrointestinal haemorrhage. *Am J Gastroenterol*. 2009;**104**:2042–2046.

13. Anthony S, Uberoi R. The current status of imaging in acute gastrointestinal haemorrhage. *Imaging*. 2006;**18**:193–197.

14. Luchtefeld MA, Senagore AJ, Szomstein M, Fedeson B, Van Erp J, Rupp S. Evaluation of transarterial embolisation for lower gastrointestinal bleeding. *Dis Colon Rectum*. 2000;**43**:532–534.

15. Funaki B, Kostelic JK, Lorenz J, Ha TV, Yip DL, Rosenblum JD, et al. Superselective microcoil embolisation of colonic haemorrhage. *AJR American J Roentgenol*. 2001;**177**:829–836.