Case Report

Infant with a Sudden, Large, Post-Extubation Subglottic Cyst

Zamzil Amin Asha'ari[1], Yusof Suhaimi[2], Ahmad Fadzil[3], Muhammad Zihni[4]

Submitted: 26 Apr 2012
Accepted: 12 Jun 2012

[1] *Department of Otolaryngology-Head & Neck Surgery, Faculty of Medicine, International Islamic University Malaysia, Jalan Hospital, 25100 Kuantan, Pahang, Malaysia*

[2] *Department of Otolaryngology, Hospital Tengku Ampuan Afzan, 25100 Kuantan, Pahang, Malaysia*

[3] *Department of Paediatric, Hospital Tengku Ampuan Afzan, 25100 Kuantan, Pahang, Malaysia*

[4] *Department of Anaesthesiology, Hospital Tengku Ampuan Afzan, 25100 Kuantan, Pahang, Malaysia*

Abstract

Acquired subglottic cyst in infancy is almost always associated with episodes of early life intubation. Most cases typically presented late, usually days to months after extubation. We report a case of a subglottic cyst with different presentation than the norm. This case highlights that subglottic cyst can present acutely, and rapidly enlarging soon after the airway extubation. As the management of a large subglottic cyst can be challenging, a close observation for early diagnosis and intervention are recommended post extubation in the high-risk cases, such as in the premature infant.

Keywords: *subglottic cyst, acquired cyst, premature infant, endotracheal intubation, airway obstruction*

Introduction

Subglottic cyst is a rare cause of stridor in infants. The largest series of subglottic cyst to date is by Lim et al., who reported 55 cases (2.6%) from 2055 series of upper airway endoscopy (1). Agada et al. found only 7 cases of subglottic cysts (0.05%) in a large cohort of 12 240 premature newborn, while Watson et al. mentioned that subglottic cyst represents only 6.8% of upper airway obstruction in their laryngotracheobonchoscopy series (2,3).

Most of the reported cases presented late, usually days to months after the trauma. We report a unique case of an infant with a large subglottic cyst, presented differently from the norm, and highlight the importance of close observation following extubation in the high risk infant.

Case Report

A 4-month-old baby girl presented with stridor two hours after airway extubation. Earlier, she had assisted ventilation via an endotracheal intubation following the diagnosis of severe pneumonia. She had a size 3.0 non-cuffed endotracheal tube (ETT) inserted, and the intubation process was reportedly uneventful. She was ventilated for four days, and at one time on day one of ventilation in the pediatric intensive care unit, the tube had dislodged; and required re-intubation with similar sized ETT. The infant had a history of premature birth at 30 weeks, with a birth weight of 1.85 kg. Pregnancy, delivery, and immediate post-natal period prior to the admission were unremarkable.

The infant became progressively breathless and the stridor was worsened within the next 4 hours. Attempts to re-intubate the baby were failed, because of an unexplained resistance when passing the tube. The baby was immediately transferred to the operation theatre, where efforts to ventilate the airway via a masked ventilation or jet ventilation were neither successful at sustaining the blood oxygen saturation for a long period. A rigid endoscopy (0-degree Hopkin's rod telescope) of the larynx revealed a large subglottic cyst totally occluding the airway (Figure 1). Subsequently, a tracheostomy was performed in the emergency setting. A suspension laryngoscopy was performed, and the cyst was aspirated with a spinal needle to yield a clear mucoid fluid (Figure 2). The cyst wall was marsupialized with

www.mjms.usm.my © Penerbit Universiti Sains Malaysia, 2012
For permission, please email:mjms.usm@gmail.com

a laryngeal micro scissor and a cupped forcep (Figure 3).

The patient was prescribed intravenous dexamethasone for three days. The infant was decannulated in the operation theatre 3 weeks later, after laryngeal endoscopy showed no evidence of cyst recurrence. A repeat endoscopy at 6 months and at one-year post-operatively revealed no recurrence of the subglottic cyst (Figure 4).

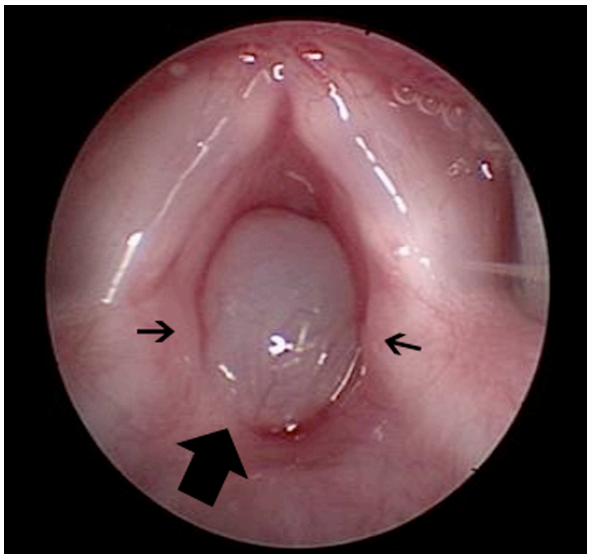

Figure 1: Endoscopic picture of the larynx showing a large subglottic cyst totally obstructing the airway. The broad-based stalk arised from the posterior wall of the left subglottis (thick arrow), just below the edematous vocal cords (thin arrow).

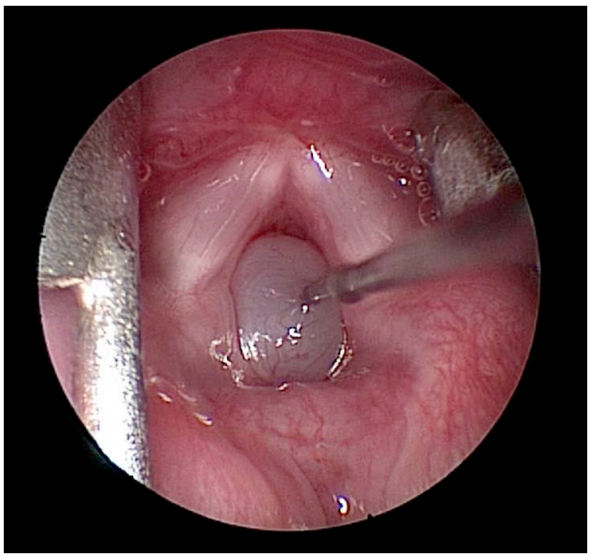

Figure 2: Endoscopic picture of the larynx showing the cyst was aspirated using a spinal needle.

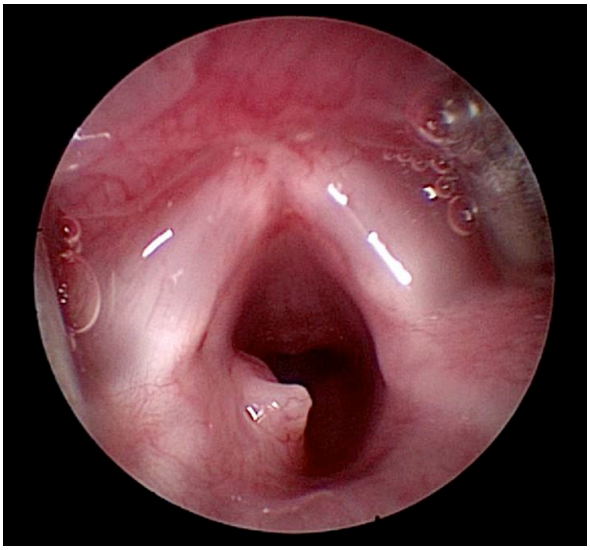

Figure 3: Endoscopic picture of the larynx after the cystic content was aspirated. The cyst wall was then excised using a microscissor and a cupped forcep.

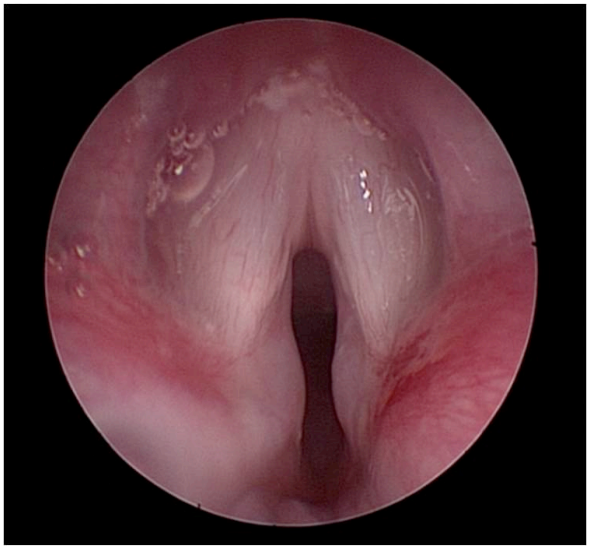

Figure 4: Endoscopic picture of the larynx at one year post-operation showing no recurrence at the subglottic region.

Discussion

Subglottic laryngeal cyst can be of congenital in origin, although it is difficult to establish if the cyst is acquired or congenital in the newborn because respiratory distress requires intubation generally without prior endoscopy. Acquired subglottic cyst is linked with prematurity and endotracheal intubation. A review of some of the largest series of subglottic cysts in the literature showed that this condition always resulted from endotracheal intubation (1–7). More than 93 percent of the cases developed in infants who were born prematurely (1,3,6). The duration of intubation does not appear to be a predictive risk factor, for these cysts can develop even after periods of intubation of less than 24 hours (6,7). Majority of the subglottic cysts, including our case, were found arising from the posterior wall of the subglottic larynx, because the area is more exposed to a contact injury from intubation.

In many of these reported series, the infants showed symptoms only after weeks to months of extubation (1,3,5,7). Our case provides unique evidence that the cyst can develop and rapidly growing following the iatrogenic injury to the mucosa in a shorter period of time. Subepithelial fibrosis as a result from intubation injury to the mucosa may obstruct the ducts of mucus glands leading to the formation of subglottic cysts (9). Traumatic intubation, multiple recurrent attempts intubation, and inappropriate size ETT used can lead to damage to the mucosa and subsequent cyst develop. The rate of cyst growth may be influenced by the severity of the injury and the abundance of mucus glands in the affected area.

Subglottic cyst is often treatable, but, if large enough can cause total airway obstruction and fatal cases have been reported (5,9). Management of the airway in infants with large subglottic cysts emphasizes on the challenges and anaesthetic considerations. In smaller lesions where the airway is partially compromised, the airway can usually be maintained by inhalational anaesthesia or jet ventilation while the airway was instrumented with a telescope by the ENT surgeon. The cyst can be decompressed by needle puncture and aspiration, and even in a very big cyst this should be the standard choice of treatment. Tracheostomy may be unavoidable in some cases, like ours, when the airway was not sustainable due to the large cyst and near total airway occlusion.

Successful management of a subglottic cyst involves early diagnosis and intervention when there is a clinical evidence of disease progression. Early intervention when the cyst is small would have avoided the need for a tracheostomy and decrease the morbidity in this case. Excision of the cysts will often be sufficient to correct the obstructed airway; however, the recurrence rate of 40% has been reported (1). Therefore, patients with subglottic cysts should be on a long-term follow up.

In conclusion, early diagnosis and intervention are vital to successfully manage a subglottic cyst. The key to early diagnosis is a strong index of suspicion; hence, we recommend a close observation period after extubation, in a child with a history of premature delivery.

Authors' Contribution

Conception and design, analysis, and interpretation of the data, drafting of the article, critical revision of the article for important intellectual content, final approval of the article, and provision of study materials or patients: ZAA
Conception and design, analysis and interpretation of the data, final approval of the article, provision of study materials or patients: SY
Analysis and interpretation of the data, drafting of the article, final approval of the article, provision of study materials or patients: AF
Final approval of the article, provision of study materials or patients: MAZ

Correspondence

Dr Zamzil Amin bin Asha'ari
MBBCh (Trinity College, University of Dublin), MMedORL-HNS (USM)
Associate Professor
Department of Otolaryngology-Head & Neck Surgery
Faculty of Medicine
International Islamic University Malaysia
Jalan Hospital, 25100 Kuantan
Pahang, Malaysia
Tel: +6019-956 4996
Fax: +609-513 4062
Email: zamzilamin@yahoo.com

References

1. Lim J, Hellier W, Harcourt J. Subglottic cysts: the Great Ormond Street experience. *Int J Pediatr Otorhinolaryngol*. 2003;**67**:461–465.

2. Agada FO, Bell J, Knight L. Subglottic cysts in children: a 10-year review. *Int J Pediatr Otorhinolaryngol.* 2006;**70**:1485–1488.

3. Watson GJ, Malik TH, Khan NA. Acquired paediatric subglottic cysts: A series from Manchester. *Int J Pediatr Otorhinolaryngol.* 2007;**71**:533–538.

4. Ransom ER, Antunes MB, Smith LP. Microdebrider resection of acquired subglottic cysts: Case series and review of the literature. *Int J Pediatr Otorhinolaryngol.* 2009;**73**:1833–1836.

5. Toriumi DM, Miller DR, Holinger LD. Acquired subglottic cysts in premature infants. *Int J Pediatr Otorhinolaryngol.* 1987;**14**:151–160.

6. Smith SP, Berkowitz RG, Phelan PD. Acquired subglottic cysts in infancy. *Arch Otolaryngol Head Neck Surg*. 1994;**120**:921.

7. Johnson LB, Rutter MJ, Shott SR. Acquired subglottic cysts in preterm infants. *J Otolaryngol.* 2005;**34**:75.

8. Steehler MK, Groblewski JC, Milmoe GJ,. Management of subglottic cysts with Mitomycin-C-A case series and literature review. *Int J Pediatr Otorhinolaryngol.* 2011;**75**:360–363.

9. Wigger HJ, Tang P. Fatal laryngeal obstruction by iatrogenic subglottic cyst. *J Pediatr*. 1968;**72**: 815–820.