Letter to the Editor

# Advanced Neuroendovascular Training and the Development of Hybrid Cerebrovascular Neurosurgery Capacity at Ministry of Health, Malaysia and Hospital Pakar Universiti Sains Malaysia

Muhammad Ihfaz Ismail[1,2], Nurfaten Hamzah[1], Siti Azleen Mohamad[3]

**Submitted:** 19 Aug 2026
**Accepted:** 25 Sep 2026
**Online:** 31 Oct 2026

[1] *Department of Neurosciences, School of Medical Sciences, Health Campus, Universiti Sains Malaysia, 16150 Kubang Kerian, Kelantan, Malaysia*

[2] *Department of Neurosciences and Brain Behaviour Cluster, Universiti Sains Malaysia Specialist Hospital, 16150 Kubang Kerian, Kelantan, Malaysia*

[3] *Department of Neurosurgery, Hospital Kuala Lumpur, 50586 Kuala Lumpur, Wilayah Persekutuan Kuala Lumpur, Malaysia*

To cite this article: Ismail MI, Hamzah N, Mohamad SA. Advanced neuroendovascular training and the development of hybrid cerebrovascular neurosurgery capacity at Ministry of Health, Malaysia and Hospital Pakar Universiti Sains Malaysia. *Malays J Med Sci*. 2026;**33(5)**:109–121. https://doi.org/10.21315/mjms-08-2026-s04

To link to this article: https://doi.org/10.21315/mjms-08-2026-s04

Dear Editor,

We read with interest the article in the *Malaysian Journal of Medical Sciences* written in 2015 with the title of "Ain't no neuroscience mountain high enough: experiences of a neurogardener" (1).

Contemporary neurosurgical practice increasingly requires the integration of technology, subspecialty expertise, and hybrid treatment paradigms. Endovascular therapy has emerged as a dominant modality in cerebrovascular care, yet open microsurgery remains essential for selected complex lesions. As endovascular therapy continues to expand in scope, the modern cerebrovascular neurosurgeon is increasingly required to function within a hybrid treatment paradigm rather than a single-modality model of care (2–5).

In Malaysia, national leadership has played a critical role in shaping subspecialty development. Dr. Azmi Alias (Figure 1), newly appointed Head of Neurosurgery Service, Ministry of Health, initiated the Area of Interest for Endovascular Programme, providing a structured pathway for Malaysian neurosurgeons to gain advanced endovascular training. A structured neuroendovascular training pathway is essential to support the safe and sustainable




**Figure 1.** Dr. Azmi Alias (Head of Neurosurgical Service, Malaysia).

 © Penerbit Universiti Sains Malaysia, 2026
This work is licensed under the terms of the Creative Commons Attribution (CC BY) (http://creativecommons.org/licenses/by/4.0/).

development of advanced cerebrovascular services in Malaysia. Such training should ideally be undertaken after completion of formal neurosurgical training, as neuroendovascular practice requires not only procedural skill but also a high level of clinical judgement, anatomical understanding, and multidisciplinary decision-making.

A total training duration of 18 months may be considered appropriate, comprising approximately 9 to 12 months of overseas fellowship exposure at a high-volume neuroendovascular centre, followed by 6 to 9 months of supervised local consolidation training. This model allows trainees to acquire advanced technical exposure in a mature service environment while facilitating adaptation of acquired skills to local systems, patient needs, and available resources.

The primary objective of this training pathway is to produce neurosurgeons who are competent in both the technical and cognitive aspects of neuroendovascular practice. At the completion of training, fellows should be able to perform neuroendovascular procedures safely, manage patients across the peri-procedural continuum, and participate in multidisciplinary treatment planning for cerebrovascular disease. In addition, fellows should be encouraged to develop an academic orientation through involvement in research related to neurovascular disease, procedural innovation, outcomes, or service delivery.

The basic curriculum should provide a strong foundation in catheter-based practice, including the use of guidewires, catheters, needles, and contrast agents, as well as principles of radiation physics, radiation safety, and angiographic interpretation. Trainees should also acquire a sound understanding of cerebrovascular pathophysiology, coagulation management, peri-procedural patient assessment, critical care of acute vascular patients, and the indications, limitations, and alternatives to endovascular treatment.

Progression to advanced training should be supported by adequate procedural exposure. A minimum experience of 200 catheter-based diagnostic and/or interventional cerebral angiographic procedures as primary operator or assistant may serve as a reasonable benchmark for foundational competency, subject to validation by the supervising trainer.

The advanced curriculum should extend beyond technical exposure to include comprehensive understanding of cerebrovascular anatomy, collateral circulation, vascular variants, cerebral blood flow physiology, and disease-specific treatment strategy. Procedural training should encompass aneurysm treatment, arteriovenous malformation and dural arteriovenous fistula embolisation, acute ischaemic stroke intervention, intracranial and extracranial angioplasty or stenting, tumour embolisation, spinal angiography and embolisation, balloon test occlusion, provocative testing, and middle meningeal artery embolisation. Familiarity with relevant pharmacologic agents—including antiplatelet therapy, anticoagulation, thrombolytics, vasoactive drugs, sedatives, and contrast media—is also essential.

Competency in neuroendovascular surgery should not be defined by technical execution alone. Fellows should also demonstrate capability in patient selection, procedural planning, complication management, neurointensive care, and longitudinal follow-up, all of which are central to safe contemporary practice.

To ensure adequate breadth of exposure, advanced fellowship training should include at least 150 therapeutic neuroendovascular procedures as operator or primary assistant. These should include representative case volumes across major treatment categories, including aneurysm treatment, ruptured aneurysm intervention, embolisation procedures, stenting or angioplasty, acute ischaemic stroke thrombectomy, head and neck embolisation, spinal angiography or embolisation, and middle meningeal artery embolisation, which is increasingly relevant in modern practice (6, 7).

In the Malaysian context, the development of such a structured training pathway is timely and strategically important. As cerebrovascular and stroke services continue to expand, a competency-based fellowship model may provide an important foundation for the development of hybrid cerebrovascular neurosurgery, improve workforce readiness, and support the long-term maturation of advanced neurosurgical services nationally.

Dr. Siti Azleen Mohamad was the first to undergo this programme at Hyogo Medical University, Japan, followed by Dr. Muhammad Ihfaz Ismail, thereby establishing a sequential model for national workforce development. Concurrent mentorship from Professor Ahmad Sobri Muda (Figure 2), Universiti Putra

Malaysia, ensured comprehensive technical and clinical exposure.

These developments, combined with ongoing infrastructure modernisation at Hospital Pakar Universiti Sains Malaysia (HPUSM), including modular theatres, intraoperative CT, and advanced spinal imaging, reflect a broader strategic vision for hybrid cerebrovascular neurosurgery. The Malaysian experience highlights the importance of leadership-driven initiatives in bridging workforce gaps, enhancing subspecialty depth, and promoting sustainable, high-quality neurosurgical services.

## Infrastructure Modernisation and Strategic Neurosurgical Expansion

HPUSM has recently received national allocation for the expansion and modernisation of its operating theatre complex, including the development of a new advanced surgical block equipped with modular operating theatres aligned with current international standards. For the Department of Neurosurgery, this development is strategically important, as modern neurosurgical care increasingly depends on an operative environment capable of supporting image-guided, precision-based, and high-acuity intervention.

One of the immediate priorities within this expansion is the transformation of the current neurosurgical operating theatre into a two-room concept, with one theatre dedicated to surgery and the other to spinal surgery. This restructuring is expected to improve case flow, optimise equipment deployment, and support the growing complexity of subspecialised neurosurgical practice. Planned integration of intraoperative CT brain for cranial surgery and Loop-X imaging/O-arm for spinal procedures further reflects the department's transition toward technologically integrated surgical care.

The clinical value of intraoperative imaging is increasingly recognised in modern neurosurgery. In cranial procedures, intraoperative CT may facilitate immediate anatomical verification, improve localisation, and support the early detection of complications such as residual tumour, residual aneurysm neck, intraoperative haemorrhage, or newly developed extra-axial bleeding (8, 9). In selected vascular cases, advanced imaging software may also support intraoperative vascular assessment. In addition to its diagnostic utility, intraoperative imaging reduces the need to transfer critically ill or ventilated patients to separate radiology facilities, thereby minimising transfer-related risks and improving perioperative workflow (8, 9).



**Figure 2.** Professor Dr. Ahmad Sobri Muda, neurointervention radiologist, Universiti Putra Malaysia (UPM).

These developments are aligned with HPUSM's broader intention to strengthen services in awake craniotomy, functional neurosurgery, brain mapping, complex skull base tumour surgery, complex cerebrovascular surgery, and advanced spinal surgery for tumour and trauma. However, infrastructure alone is insufficient. The maturation of such services requires parallel investment in specialist training and subspecialty competency.

## Advanced Neuroendovascular Training at Hyogo Medical University

The Area of Interest for Endovascular Programme, launched by Dr. Azmi Alias, provides Malaysian neurosurgeons with structured exposure to advanced neuroendovascular procedures. Dr. Siti Azleen Mohamad (Figure 3) led the cohort as the first trainee, undergoing intensive training at Hyogo Medical University under Professor Shinichi Yoshimura, complemented by mentorship from Professor Ahmad Sobri Muda. She was followed by Dr. Muhammad Ihfaz Ismail, reflecting the sequential strategy to scale national expertise. Dr. Muhammad Ihfaz Ismail was invited to undergo advanced neuroendovascular training at Hyogo Medical University under a

programme established and approved by the World Federation of Neurosurgical Societies. This attachment, conducted under the supervision of Professor Shinichi Yoshimura (Figures 4 and 5), offers exposure not only to advanced procedural techniques but also to the operational and clinical architecture of a mature cerebrovascular service.

Hyogo Medical University is among the busiest referral centres for neuroendovascular intervention in Japan and is equipped with four interventional radiology suites, including one dedicated specifically to the Department of Neurosurgery. Approximately 95% of cerebrovascular cases are managed through endovascular techniques, while the remaining 5% require open microsurgical treatment. Although endovascular therapy has become the dominant modality in many cerebrovascular conditions, open surgery remains indispensable in selected lesions such as moyamoya disease, certain cases of carotid artery stenosis, and patients with unfavourable vascular access anatomy, severe tortuosity, complete carotid occlusion, or unstable thrombotic plaque (2, 10).

The neuroendovascular service at Hyogo Medical University operates on a 24-hour, 7-day basis, reflecting the urgency of acute cerebrovascular care. Elective procedures are performed throughout the week, with an average of three to four cases daily, in addition to emergency interventions such as urgent coiling for ruptured aneurysm and mechanical thrombectomy for acute large vessel occlusion stroke. Routine elective procedures include standalone coiling, stent-assisted coiling, balloon-assisted coiling, WEB device deployment, flow diverter placement, embolisation of dural arteriovenous fistula, middle meningeal artery embolisation, and carotid artery stenting. Exposure to this breadth of practice is highly relevant to the future development of cerebrovascular and acute stroke services at HPUSM.



**Figure 3.** Dr. Siti Azleen successfully completed endovascular training and received formal certification from Professor Shinichi Yoshimura.




**Figure 4.** a) Dr. Muhammad Ihfaz on his first day reporting to Professor Dr. Shinichi Yoshimura; b) The book entitled *A Beginner's Guide to Neuroendovascular Therapy* written by Professor Shinichi Yoshimura and his team.

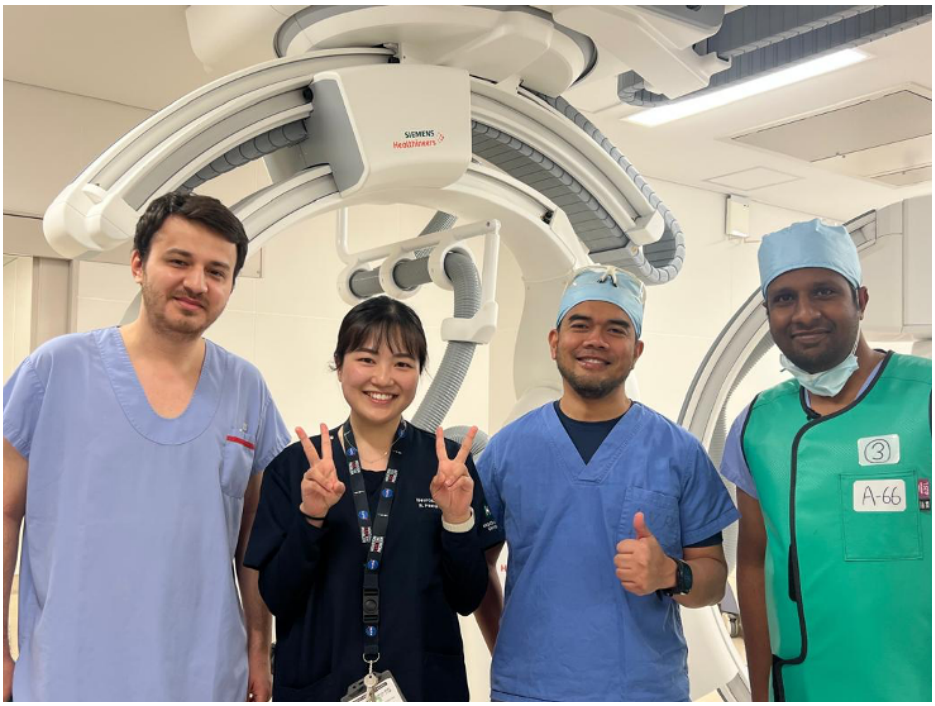


**Figure 5.** Other colleagues of endovascular trainees together with Dr. Muhammad Ihfaz; from left: Dr. Farrukh from Uzbekistan; Dr. Hashimoto from Osaka, Japan; and Dr. Ebby Sabastian from Kerala, India.

Training under this initiative covers procedural mastery, workflow optimisation, emergency stroke management, and the operational framework of a high-volume cerebrovascular service. By integrating these skills with domestic service development at HPUSM, the programme ensures that Malaysia's neurosurgeons are equipped to deliver hybrid microsurgical-endovascular strategies, improve acute stroke care, and contribute to evidence-based cerebrovascular management nationally.

## National Workforce Relevance and the Malaysian Context

The strategic relevance of advanced subspecialty training is particularly evident when considered within the broader Malaysian neurosurgical workforce. Universiti Sains Malaysia has long been one of the principal contributors to specialist training in neurosurgery and neurosciences in the country. Figures 6 to 9 depict the current students at Universiti Sains Malaysia.

As of the 2026 academic year, Universiti Sains Malaysia (USM) has produced approximately 160 neurosurgeons. Of these, 48 are in private practice, one is practising overseas, one has passed away, and one is no longer in active clinical practice, leaving 109 neurosurgeons currently serving within the Malaysian public healthcare system.

Among those in public service, 94 are serving under the Ministry of Health and 15 within the Ministry of Higher Education or public university system. Against an estimated Malaysian population of approximately 34 million, this places the national neurosurgeon-to-population ratio at approximately 1:300,000 to 1:350,000. By comparison, ratios reported in more mature systems such as Japan are substantially lower, with estimates in the range of 1:100,000 to 1:150,000, reflecting a much denser specialist workforce (11, 12).

This disparity has implications beyond numerical shortage alone. It affects regional access, subspecialty service maturity, emergency coverage, on-call sustainability, and the ability of centres to develop advanced treatment capability. Accordingly, future neurosurgical development in Malaysia should not be framed solely around increasing workforce numbers, but also around cultivating subspecialty depth, technical versatility, and institutional readiness.


Dr. Faris Suhaimi Razali


Dr. Fadhli Suliman


Dr. Azwa Maulat Kamarul Bahri


Dr. Aaron Lee Zhi Wen


Dr. Muhammad Afifi Shukri Soo


Dr. Kong Keen Chee


Dr. Jap Xin Yi


Dr. Mohamad Haikal Zainol


Dr. Muhammad Zakwan Zulkifli


Dr. Saktivadivelu Letchmanan


Dr. Nik Zulkifli Nik Ab Rahman


Dr. Yop Wing Hang


Dr. Surin Etican Paramasevan


Dr. Tharsyininair Thilagar


Dr. Ismail Junaih Shareef


Dr. Yuvaraaj Lechumanan


Dr. Shaun Aaron Jeevan

**Figure 6a.** Year 1—Master of Neurosurgery students (Intake 2025).


Dr. Azali Hafiz Yaffie Nuhairi


Dr. Fikri Indra Prastanta Didi Indra Tjahja


Dr. Mohammad Faris Mohd Hithir


Dr. Muhammad Hakim Mohammad Assri


Dr. Pavankumar Balachandran


Dr. Premkumar Ravichandran


Dr. Raghuvaran Raja


Dr. Kausar Kamarulazman


Dr. Tan Sian Won


Dr. Thenmolle Arumugam


Dr. Wan Nurul Sakinah Wan Mohd Azaharuddin

**Figure 6b.** Year 1—Master of Neurosurgery students (Intake 2026).




**Figure 7.** Master of Clinical Psychology (Cohort 7).




**Figure 8.** Master of Clinical Psychology (Cohort 8).



Mohamed Nasrun
Mohamed Zikrillah

**Figure 9.** PhD Clinical Psychology.

## Acute Stroke Services and the Need for Hybrid Cerebrovascular Capability

The importance of endovascular and hybrid cerebrovascular expertise has become even more apparent with the recent inauguration of the Acute Stroke Unit at HPUSM in January 2026, marking an important institutional step toward the functions of a comprehensive stroke centre. In the modern stroke era, mechanical thrombectomy has become a standard treatment for acute ischaemic stroke due to large vessel occlusion, and its integration into tertiary neurosciences services is increasingly expected (4, 13).

However, the expansion of such services in many settings remains constrained by the cost of devices, the need for trained personnel, and the organisational requirements of rapid-response stroke systems. Consequently, the development of endovascular capability must be approached not as a standalone procedural ambition, but as part of a broader systems-based evolution in cerebrovascular care. This must coexist with continued emphasis on prevention, early recognition, timely referral, and appropriate patient selection.

Beyond stroke, endovascular therapy is increasingly relevant in the management of giant aneurysms, fusiform aneurysms, cavernous aneurysms, and other complex vascular lesions where treatment may be best achieved through endovascular, microsurgical, or combined strategies. In this setting, the role of the contemporary cerebrovascular neurosurgeon increasingly depends on a hybrid knowledge base, including an understanding of vascular dominance, hemodynamic flow, collateral sufficiency, and the physiological consequences of parent vessel sacrifice (2, 3, 14).

One important example of this integrated approach is the balloon occlusion test, which remains a useful physiological assessment tool in selected vascular lesions. Balloon occlusion test is particularly relevant when treatment planning may involve deliberate vessel sacrifice, as it provides functional information regarding collateral circulation and cerebral tolerance to occlusion (14).

## Illustrative Institutional Experience

The practical value of hybrid cerebrovascular strategy was recently demonstrated in a complex aneurysm case managed at HPUSM under the guidance of Dato' Professor Jafri Malin Abdullah. The patient was a 34-year-old man referred from Hospital Sultanah Nur Zahirah, Terengganu, who presented with right-sided headache and partial right ptosis. Imaging demonstrated a large unruptured right paraclinoid aneurysm, a lesion that presents considerable technical and hemodynamic complexity.

As part of preoperative planning, the patient underwent a balloon occlusion test of the right internal carotid artery (ICA) with concurrent somatosensory evoked potential (SSEP) and motor evoked potential monitoring for 30 minutes in September 2025. During the occlusion period, there was no clinical neurological deficit and no significant change in electrophysiological baseline, suggesting adequate collateral perfusion, most likely via the anterior communicating artery (ACOM).

Despite these reassuring findings, the complexity of the lesion warranted an added safety strategy. The patient subsequently underwent a right superficial temporal artery to middle cerebral artery (STA–MCA) bypass prior to ligation of the extracranial ICA. Follow-up CT angiography confirmed aneurysm resolution, absence of new infarction, and maintained bypass patency (Figures 10 and 11). This case illustrates the practical value of combining endovascular physiological assessment with microsurgical revascularisation in the management of complex cerebrovascular pathology.

Another challenging case from Hospital Kuala Lumpur (HKL) involved a patient with a complex dural arteriovenous fistula (dAVF) that persisted despite three previous attempts at endovascular treatment using transarterial embolisation and transvenous embolisation.

Following unsuccessful conventional endovascular interventions, a hybrid surgical–endovascular approach was undertaken on 13 July 2026. The procedure was led by

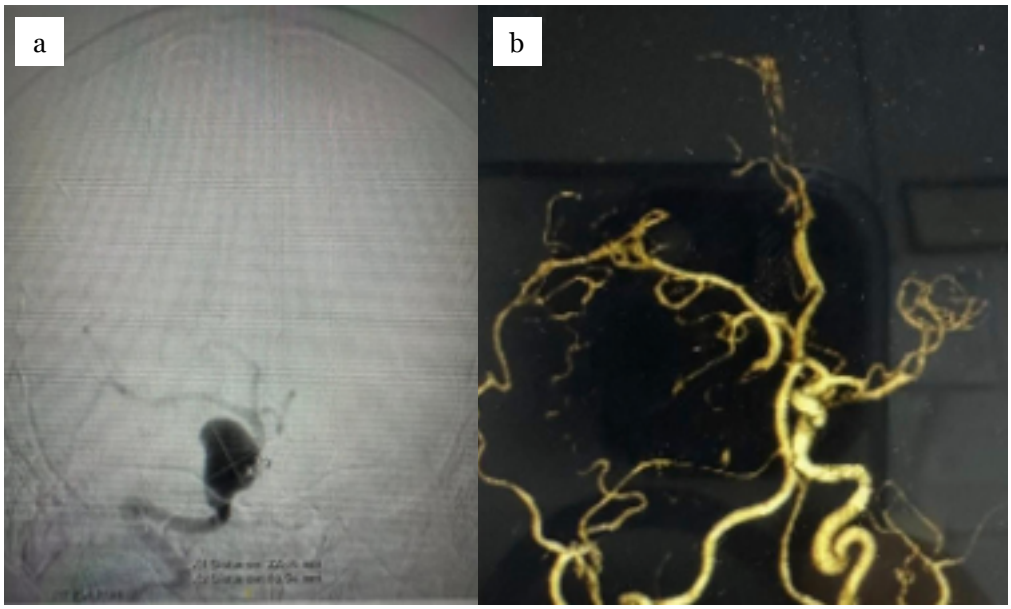


**Figure 10.** a) Right big paraclinoid aneurysm (22 mm × 18 mm); b) CT angiogram: resolution of right paraclinoid aneurysm and patency of right STA–MCA bypass.




**Figure 11.** a) Incision planned at right side of scalp for STA–MCA bypass and incision at neck for proximal carotid artery ligation; b) No facial weakness or asymmetry post operation; c) Both wounds at scalp and neck healed well on day 7 of operation, after removal of sutures; d) Patient ambulating well in ward without any neurological deficit and allowed discharge on day 7 post operation.

Dr. Siti Azleen, under the supervision of Dr. Ahmad Sobri from UPM and the guidance of Dr. Azmi Alias, Head of the Department of Neurosurgery, HKL (Figures 12 and 13).

The procedure was performed in the Neuro Hybrid Operating Room equipped with an integrated angiography suite at Hospital Tunku Azizah (HTA), Kuala Lumpur. This innovative strategy combined craniotomy with direct puncture of the draining vein, alongside femoral arterial access, facilitating targeted endovascular treatment of the complex dAVF.

The availability of a dedicated hybrid operating theatre with integrated angiographic capabilities enabled seamless integration of microsurgical and endovascular techniques within a single operative setting. This multidisciplinary approach provided greater procedural flexibility, enhanced intraoperative visualisation, and facilitated a more controlled

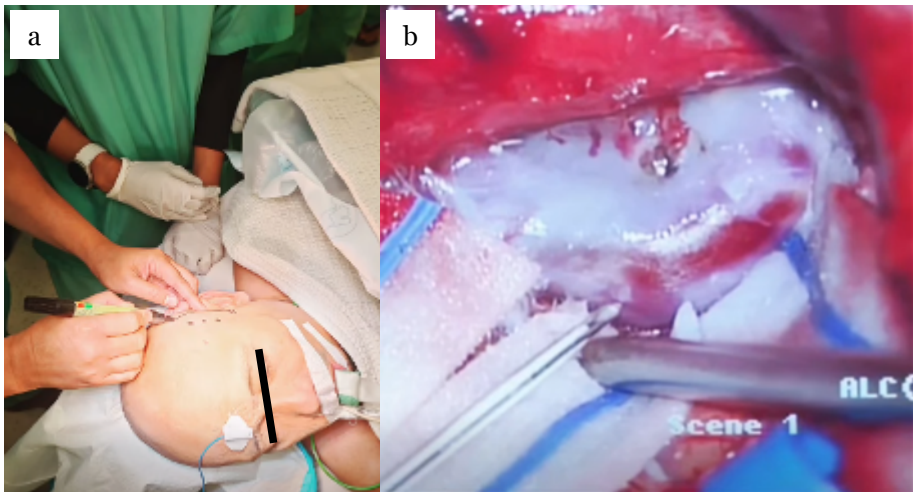


**Figure 12.** a) Drawing of incision on left temporo-parietal scalp region; b) Identification of left Sylvian vein and needle was ready to puncture for direct cranial transvenous access.

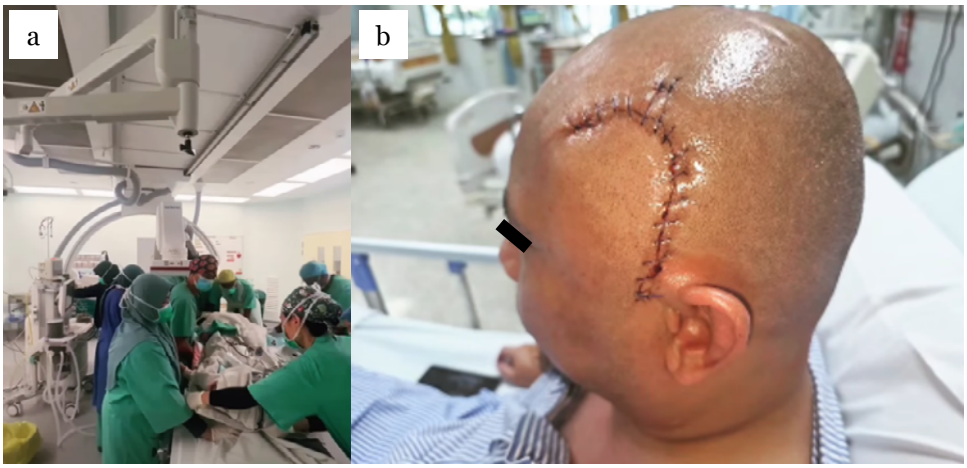


**Figure 13.** a) Patient was transferred to the angiogram bed for the endovascular procedure after getting direct transcranial transvenous access; b) Postoperatively, the patient was extubated uneventfully without any complication.

treatment strategy for this challenging cerebrovascular pathology.

This case highlights the importance of hybrid neurosurgical facilities, advanced neurovascular expertise, and multidisciplinary collaboration in managing complex dAVFs that remain refractory to conventional endovascular treatment.

Special acknowledgement and appreciation are extended to all teams involved, including PUTRA CNS, Interventional Radiology (HKL), Neuro Anaesthetics (HKL), and the HTA Operating Theatre team, whose expertise, dedication, and collaborative efforts were instrumental in facilitating this complex procedure.

The case exemplifies the continued advancement of hybrid cerebrovascular neurosurgery in Malaysia, demonstrating how the integration of open surgical and endovascular techniques can expand treatment options for challenging neurovascular conditions.

## A Legacy of Excellence in Neurosurgery, Education, and Global Leadership

We would like to take this opportunity to acknowledge and congratulate Professor Dato' Dr. Jafri Malin Abdullah on his recent prestigious international achievements and recognitions. These remarkable milestones reflect his outstanding contributions to neurosurgery, medical education, scientific leadership, international collaboration, and global brain health advocacy (Figures 14–17).

His accomplishments have not only brought great honour and recognition to USM but have also elevated the standing of the Malaysian neurosurgical community within the international scientific and medical arena.

These achievements serve as a source of immense pride and inspiration to fellow neurosurgeons, researchers, medical educators, and future generations, while further strengthening Malaysia's presence and reputation in the global neuroscience community. Our heartfelt congratulations to Professor Dato' Dr. Jafri Malin Abdullah on these well-deserved recognitions and remarkable achievements.




**Figure 14.** Participation in Brain Days at the United Nations General Assembly (UNGA) 2026, USA. His participation highlights Malaysia's involvement in international discussions and collaborations aimed at advancing brain health, neuroscience research, and global awareness of neurological disorders.




**Figure 15.** Recipient of the 2026 National Academy of Medicine Distinguished Educator Award. This prestigious award recognises his outstanding contributions to medical education, mentorship, and the development of future generations of healthcare professionals. The award was conferred by His Royal Highness the Sultan of Pahang during the 26th Annual General Meeting and 24th Annual Scientific Meeting of the Neurosurgical Association of Malaysia 2026, marking another significant milestone in his distinguished academic and professional career.




**Figure 16.** Elected Fellow of the Islamic World Academy of Sciences in Neurosciences. This distinction recognises his contributions to neuroscience and reflects international acknowledgement of Malaysian scientific expertise and academic leadership.




**Figure 17.** Appointed Commissioner of the Nature Medicine Commission on Brain Health for Economic Resilience. Under the Global Brain Economy Initiative, this appointment provides an opportunity to contribute to international efforts linking brain health, scientific advancement, societal wellbeing, and economic resilience.

## Conclusion

The future of Malaysian cerebrovascular neurosurgery depends not only on expanding specialist numbers but also on strategic, leadership-driven initiatives that develop subspecialty depth, advanced infrastructure, and hybrid clinical capability. The Area of Interest for the Endovascular Programme, initiated by Dr. Azmi Alias, exemplifies how national leadership can catalyse subspecialty training and workforce development. The sequential training of Dr. Siti Azleen and Dr. Muhammad Ihfaz Ismail at Hyogo Medical University, coupled with mentorship from Professor Ahmad Sobri Muda, illustrates how leadership, international exposure, and institutional investment converge to strengthen complex neurosurgical services. This integrated approach provides a sustainable model for advancing hybrid cerebrovascular neurosurgery, acute stroke management, and high-quality patient care in Malaysia.

## Conflict of Interest

None.

## Authors' Contributions

Conception and design: MII
Analysis and interpretation of the data: MII
Drafting of the article: MII
Critical revision of the article for important intellectual content: SAM
Final approval of the article: SAM
Provision of study materials or patients: NH
Statistical expertise: NH
Administrative, technical, or logistic support: NH
Collection and assembly of data: NH

## Correspondence

Dr. Muhammad Ihfaz Ismail
MBBS (IIUM), Master of Neurosurgery (USM)
Department of Neurosciences,
School of Medical Sciences, Health Campus,
Universiti Sains Malaysia,
16150 Kubang Kerian,
Kelantan, Malaysia
Tel: +609-767 6778
Email: ihfazrose5919@usm.my

## References

1. Abdullah JM. Ain't no neuroscience mountain high enough: experiences of a neurogardener. *Malays J Med Sci*. 2015;**22(3)**:1–6.

2. Murayama Y, Arakawa H, Ishibashi T, Kawamura D, Ebara M, Irie K, et al. Combined surgical and endovascular treatment of complex cerebrovascular diseases in the hybrid operating room. *J Neurointerv Surg*. 2013;**5(5)**:489–493. https://doi.org/10.1136/neurintsurg-2012-010382

3. Rychen J, Ferreira C, Ferreira MY, Croft Z, Weiger VF, Thomas G, et al. Contemporary indications and outcomes of open surgical cerebral aneurysm management in the endovascular era. *Front Surg*. 2026;**13**:1811416. https://doi.org/10.3389/fsurg.2026.1811416

4. Powers WJ, Rabinstein AA, Ackerson T, Adeoye OM, Bambakidis NC, Becker K, et al. Guidelines for the early management of patients with acute ischemic stroke: 2019 update to the 2018 guidelines for the early management of acute ischemic stroke: a guideline for healthcare professionals from the American Heart Association/American Stroke Association. *Stroke*. 2019;**50(12)**:e344–e418. https://doi.org/10.1161/STR.0000000000000211

5. Lawton MT, Lang MJ. The future of open vascular neurosurgery: perspectives on cavernous malformations, AVMs, and bypasses for complex aneurysms. *J Neurosurg*. 2019;**130(5)**:1409–1425. https://doi.org/10.3171/2019.1.JNS182156

6. de Almeida Monteiro G, Mutarelli A, Gonçalves OR, Marinheiro G, Santana L, Fukunaga CK, et al. Middle meningeal artery embolization for chronic subdural hematoma: a meta-analysis of randomized controlled trials with trial sequential analysis. *Neurosurg Rev*. 2025;**48(1)**:358. https://doi.org/10.1007/s10143-025-03464-7

7. Fiorella D, Monteith SJ, Hanel R, Atchie B, Boo S, McTaggart RA, et al. Embolization of the middle meningeal artery for chronic subdural hematoma. *N Engl J Med*. 2025;**392**:855–864. https://doi.org/10.1056/NEJMoa2409845

8. Prada F, Del Bene M, Mattei L, Casali C, Filippini A, Legnani F, et al. Fusion imaging for intra-operative ultrasound-based navigation in neurosurgery. *J Ultrasound*. 2014;**17(3)**:243–251. https://doi.org/10.1007/s40477-014-0111-8

9. Tandon V, Mahapatra AK. Intraoperative magnetic resonance imaging in neurosurgery. *Indian J Neurosurg*. 2017;**6(3)**:159–162. https://doi.org/10.1055/s-0037-1608957

10. Fujimura M, Tominaga T, Kuroda S, Takahashi JC, Endo H, Ogasawara K, et al. 2021 Japanese guidelines for the management of moyamoya disease: guidelines from the Research Committee on Moyamoya Disease and Japan Stroke Society. *Neurol Med Chir*. 2022;**62(4)**:165–170. https://doi.org/10.2176/jns-nmc.2021-0382

11. Department of Statistics Malaysia. *Current population estimates, Malaysia, 2026*. Putrajaya: Department of Statistics Malaysia; 2026.

12. Iihara K, Tominaga T, Saito N, Suzuki M, Date I, Fujii Y, et al. The Japan neurosurgical database: overview and results of the first-year survey. *Neurol Med Chir*. 2020;**60(4)**:165–190. https://doi.org/10.2176/nmc.st.2019-0211

13. Goyal M, Menon BK, van Zwam WH, Dippel DWJ, Mitchell PJ, Demchuk AM, et al. Endovascular thrombectomy after large-vessel ischaemic stroke: a meta-analysis of individual patient data from five randomised trials. *Lancet*. 2016;**387(10029)**:1723–1731. https://doi.org/10.1016/S0140-6736(16)00163-X

14. van Rooij WJJ, Sluzewski M, Metz NH, Nijssen PCG, Wijnalda D, Rinkel GJE, et al. Carotid balloon occlusion for large and giant aneurysms: evaluation of a new test occlusion protocol. *Neurosurgery*. 2000;**47(1)**:116–122. https://doi.org/10.1097/00006123-200007000-00025